



University of Maryland, 2113 Animal Science Building
College Park, Maryland 20742-2317
Telephone: 301-405-6085, FAX: 301-314-9412
E-mail: nrac@umd.edu Web: <http://www.nrac.umd.edu>

Fish Diseases: Mycobacteriosis of Fish

Paul R. Bowser, Department of Microbiology and Immunology College of Veterinary Medicine
Cornell University, Ithaca, New York 14853-6401

Mycobacteriosis is a bacterial infection that has been known for many years as a common disease found in aquarium fish. The disease has traditionally been thought of as an illness of older fish in an aquarium population. Infected fish may show a variety of disease symptoms, or may show no signs of disease at all. The disease is also known in fish cultured under intensive conditions, particularly those in closed recirculation production systems. Of particular concern is the fact that bacteria involved in mycobacteriosis of fish, several members of the bacterial genus *Mycobacterium*, can infect humans. The bacteria can gain entrance into the human body through small cuts and abrasions on the skin. Because the bacteria are adapted to cool temperatures, they can establish infections in the cooler part of the human body, in the skin.

There are a number of bacteria that may be involved in mycobacteriosis in fish. Some of the names reported in the literature include: *Mycobacterium marinum*, *M. fortuitum* and *M. chelonae*. These bacteria occur naturally in the aquatic environment, especially in environments with low dissolved oxygen concentrations, low pH, high organic loads and high water temperatures. These conditions might be commonly found in commercial production aquaculture systems.

Historically, mycobacteriosis in fish was problematic in salmonid culture during the period before commercially available pelleted rations were available. At that

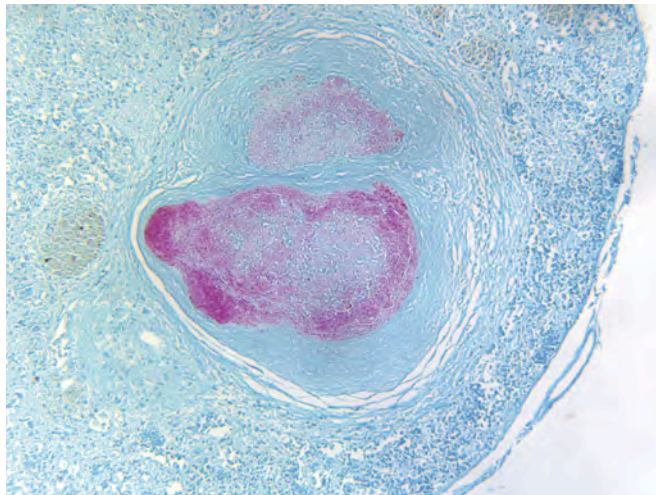
time, it was not uncommon to utilize offal (waste product) from fish processing plants as part of the ration for cultured fish. This material was feed to the fish in an unpasteurized condition. If the offal was contaminated with mycobacteria, that bacteria infected the fish via the oral route. When commercially pelleted rations became the norm in salmonid production systems, mycobacterial infections became a rarity. In the contemporary fish production environment, mycobacteriosis appears to be most closely associated with closed recirculation aquaculture systems.

The Disease: Mycobacteriosis of Fish

Mycobacteriosis is a systemic bacterial infection that can cause a variety of external and internal signs of disease. Fish may exhibit variable amounts of hemorrhage on the skin and fins, external ulcers, frayed fins, swollen abdomen, and an exophthalmic (“pop-eye”) condition in the eyes. In some cases the condition of lepidorthosis may be seen. In this condition, scales appear to protrude away from the body and give the fish a “pine cone” appearance. This condition is due to the accumulation of ascites (fluid) in individual scale pockets. Internally, the most classic lesion is the granuloma (Figure 1). Granulomas appear as nodules in the internal organs or in the mesenteries. The granuloma is made up of concentric layers of macrophages (phagocytic cells

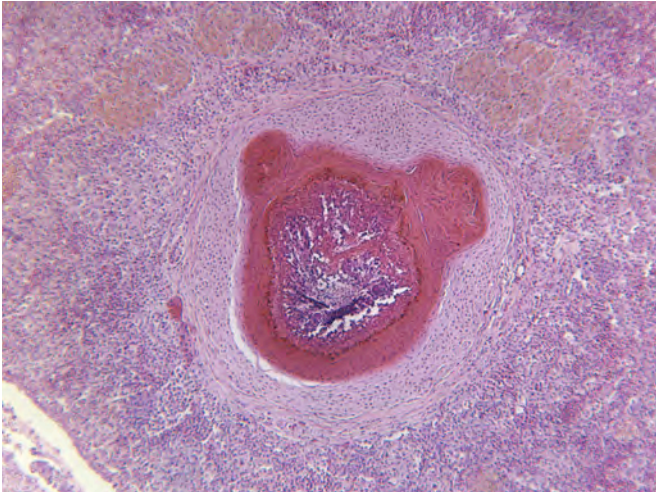

Figure 1. A mycobacterial granuloma in a cultured hybrid striped bass (Hematoxylin and Eosin Stain). This histopathology is a common observation in fish infected with mycobacteria.



A mycobacterial granuloma in a cultured hybrid striped bass that has been stained with a Ziehl-Neelsen Acid Fast Stain. This special stain allows a better visualization of the bacteria due to their red color.

that are part of the immune system of fish) that are an attempt by the fish to “wall off” the infection. Other internal lesions may include hemorrhage and accumulation of ascites in the coelomic cavity. It is important to note that, while these signs may be of some supportive diagnostic value (especially the granuloma); they are also common signs of disease due to a wide variety of causes. It should also be noted that the appearance of a fish with a mycobacterial infection can be extremely variable. One might see fish with all of the above disease signs, while another infected fish may show few.

Diagnosis of mycobacteriosis of fish requires the processing of diagnostic samples by an appropriately qualified laboratory. Typically, the disease is diagnosed based on microscopic evaluation of tissues processed for histopathology. The pathologist will evaluate the tissues for the presence of granulomas. Part of this evaluation is to perform a special stain (Ziehl-Neelsen Acid Fast Stain) on the tissues (Figure 2). This stain specifically stains the mycobacteria due to the structure of the bacterial cell wall. Some laboratories will also culture the bacterium, although this requires a special medium and the bacterium bacteria may take several weeks to grow on the agar plate. There area also a number of molecular-based tests (polymerase chain reaction = PCR) that have been developed for the various mycobacteria that infect fish.

Management Strategies for Mycobacteriosis in Fish

In spite of what may be found in the popular aquarium literature, there are no known effective treatments to control mycobacterial infections in fish. The best option for the fish culturist is to practice sound fish husbandry. Providing a good environment in terms of water quality and nutrition will go a long way in avoiding or reducing the potential impact of mycobacteriosis in a group of fish. Any dead fish in a production system should be removed from the system as soon as they are observed. Because mycobacteria can exist in biofilms, the system should be disinfected between production lots of fish if that is possible. Any equipment (nets, boots, buckets, scrub brushes) should be disinfected between uses. These same practices will also limit the spread of other fish diseases.

Of special concern is the fact that the bacterium is zoonotic (*i.e.*, it can infect humans). While such infections are by no means common in the keeping of aquarium fish or in the fish production environment, they do occur. If a worker has a nodule or ulceration on the skin (typically on the hands and/or arms) that does not appear to heal as usual, he or she should contact their personal physician for proper medical evaluation and treatment. If there have been recently diagnosed cases of mycobacteriosis in fish at the production facility, alerting the physician to that fact would be appropriate. As is the case with many diseases, proper personal cleanliness, including hand washing, can be extremely helpful in avoiding infections.

Summary

Mycobacteria are a group of bacteria that are commonly found in the aquatic environment. They have the ability to infect fish, with infections most commonly seen in closed recirculating aquaculture systems. No therapeutic compounds are known to be effective in treating mycobacterial infections in fish. Therefore, the best management strategy is for the aquaculturist to practice sound production methods and provide the best environment possible for the fish. Attention to good biosecurity principles is also important. Although rare, human infections by mycobacteria can occur. The aquaculturist should be alert to the development of nodules or ulcers on the skin and seek appropriate medical attention for evaluation.

General Web Site of Interest

Center for Food Security and Public Health:
<http://www.cfsph.iastate.edu/>

Acknowledgements



United States
Department of
Agriculture

National Institute
of Food and
Agriculture

This work was conducted with the support of the Northeastern Regional Aquaculture Center, through grant number 2006-38500-17605 from the National Institute of Food and Agriculture (NIFA), U.S. Department of Agriculture. Any opinions, findings, conclusions, or recommendations expressed in this publication are those of the authors and do not necessarily reflect the view of the U.S. Department of Agriculture.

References

- Decostere, A., K. Hermans, and F. Haesebrouck. 2004. Piscine mycobacteriosis: a literature review covering the agent and the disease it causes in fish and humans. *Veterinary Microbiology* 99:159-166.
- Francis-Floyd, R. and R. Yanong. 2002. Mycobacteriosis in Fish. Florida Cooperative Extension Service, Institute of Food and Agricultural Sciences, University of Florida. Fact Sheet VM-96. 4 pp.
- Jacobs, J.M., C.B. Stine, A.M. Baya and M.L. Kent. 2009. A review of mycobacteriosis in marine fish. *Journal of Fish Disease* 32:119-130.